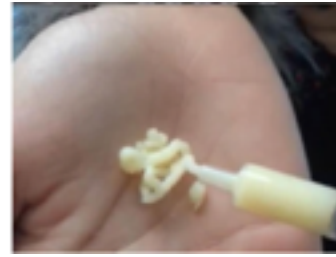
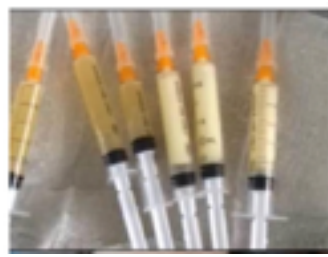
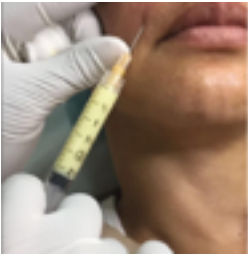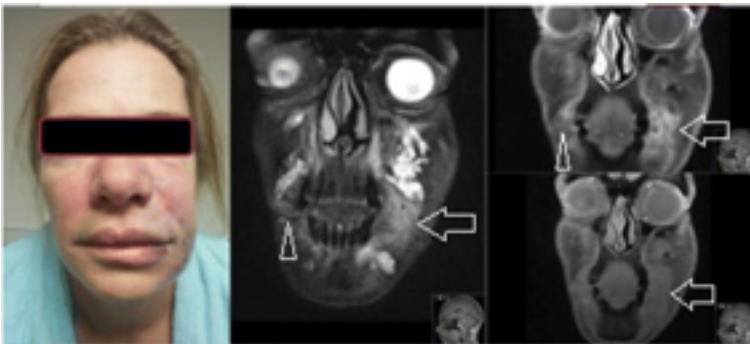
Why I use natural fillers only?



CellPRP
CELLULAR REGENERATION

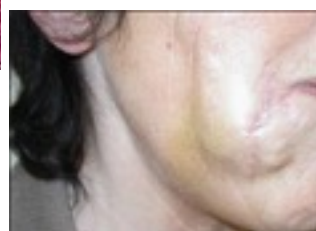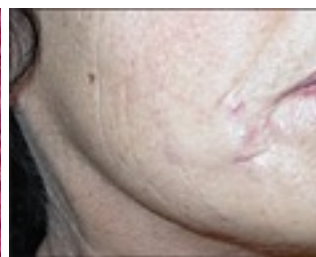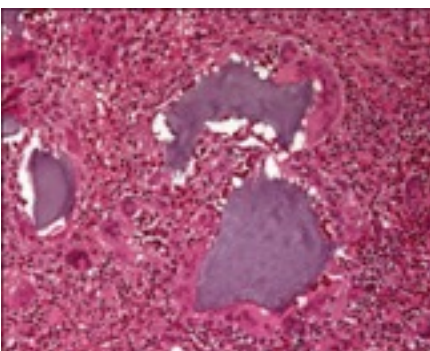
MRI in detecting facial cosmetic injectable filler complications, 7 years after treatment.

Published by Dr Assaf Persitz & Dr Lior Heller,
BMC Publication - Head & Face Medicine - 06 September 2016



In England alone in 2019,

- **934** patients arrived at A&E with complications with aesthetic treatments
- **623** were dermal filler relaxed after a treatment approx. 7 years ago



Here is a histopathology photograph of the HA injection specimen showing clumps of acrylic hydrogel based giant cells and huge mass type of disease-fighting white blood cell causing a protrusion.

Managing Complications of
Fillers: Rare and Not-So-Rare

J Cutan Aesthet Surg. 2015 Oct-Dec